

# 260 - WHITE MATTER MICROSTRUCTURAL ALTERATIONS IN PATIENTS WITH PERSISTENT HEADACHE AFTER COVID-19 INFECTION: AN EXPLORATORY STUDY

Álvaro Planchuelo-Gómez<sup>1</sup>, David García-Azorín<sup>2</sup>, Ángel L. Guerrero<sup>2</sup>, Santiago Aja-Fernández<sup>1</sup>, Margarita Rodríguez<sup>3</sup>, Raúl Moro<sup>3</sup>, Rodrigo de Luis-García<sup>1</sup>

<sup>1</sup> Imaging Processing Laboratory, Universidad de Valladolid, Valladolid, Spain

<sup>2</sup> Headache Unit, Department of Neurology, Hospital Clínico Universitario de Valladolid, Valladolid, Spain

<sup>3</sup> Department of Radiology, Hospital Clínico Universitario de Valladolid, Valladolid, Spain

## INTRODUCTION

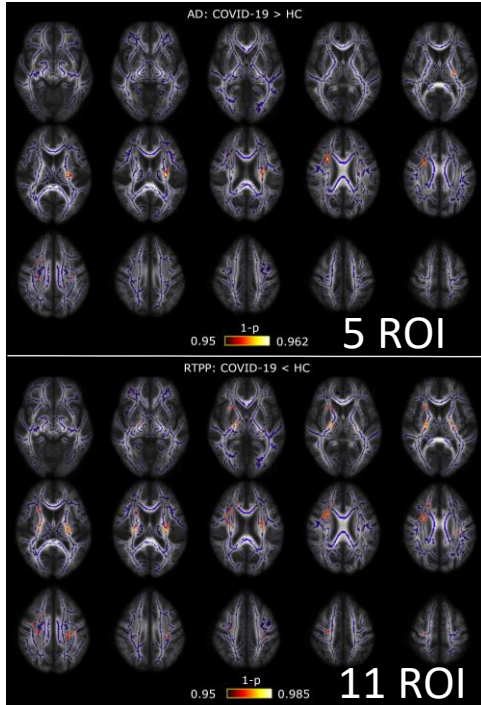
**COVID-19: Headache** is among the most frequent neurological symptoms, including long-term effects [1]

**Objective:** Evaluate the white matter structural properties of patients with persistent headache after COVID-19

## METHODS

**Sample:** **10 patients** (54.0 years; 42-65 years; 9 women) + **10 controls (HC)** (54.5 years; 42-64 years; 9 women)

Diffusion MRI measures: **DTI** (FA, MD, RD, AD) + **AMURA** [2] (RTOP, RTAP, RTPP) (see bottom-right) → Comparison via **TBSS**



## CONCLUSIONS

**COVID-19 headache:** possible association with **axonal alterations** (barriers in axial orientation)

## REFERENCES

- [1] Logue JK, et al., *JAMA Netw Open* (2021)  
[2] Aja-Fernández et al., *PLoS ONE* (2020)

